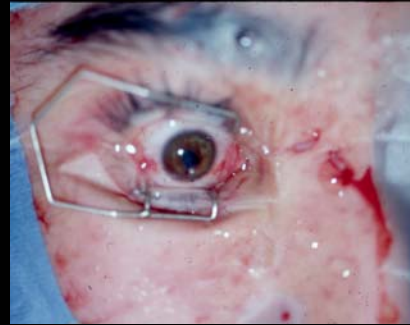

**The OTA AAOS US Army  
Visiting Orthopaedic Trauma  
Surgeon Program**

**Steven J Morgan MD**

**Fall Clinics 2008  
Montrose, Colorado**

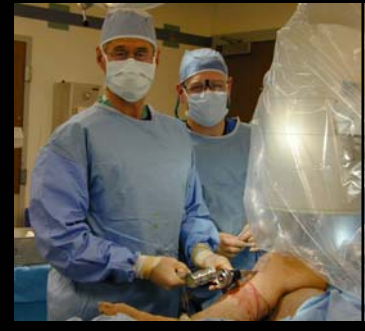

**The Program**

- Andy Pollak MD- OTA
- Richard Kyle MD- AAOS
- Col. Jim Ficke MD US Army
  - Senior Orthopaedic consultant US Army
- Col. Roman Hayda US Army
  - Orthopaedic Trauma Surgeon US Army

**AAST Program**

- Visiting US Trauma Surgeons



**Concept**

- Send Experienced Orthopaedic Trauma Surgeon
- Provide Clinical Orthopaedic Trauma Expertise
- Provide CME
- Develop Relationships Younger Surgeons
  - Mentoring
- Review & Comment on Military Medical System
  - Consultant

**Concept**

- Get Experience in War Trauma
- Provide Regional Expertise For War Like Injuries in the US

## Logistics/Selection

- Ten Years Experience
- Fellowship Trained
- Primary Trauma Practice
- Application & Essay
- Two Week Commitment

## Logistics/Selection

- Mountain of Paper Work
- Red Cross Volunteer
- Hospital Privileges
- Background Check

## Location

- Landstul Regional Medical Center
  - Landstul Germany
  - Level II Trauma Center
    - ACS Criteria
  - Only Center out of CONUS with This Designation



## RAB

- Military Air Hub in Europe
  - Afghanistan
  - Iraq

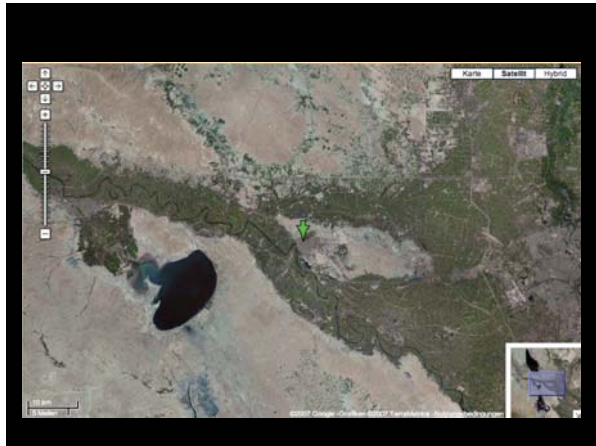


## Daily Activity

- Morning Report
- Surgery
  - 5-6 Cases Day
- Incoming Casualty Evaluation
  - 5-10 a Day

## Where Does It All Start The Evacuation Chain

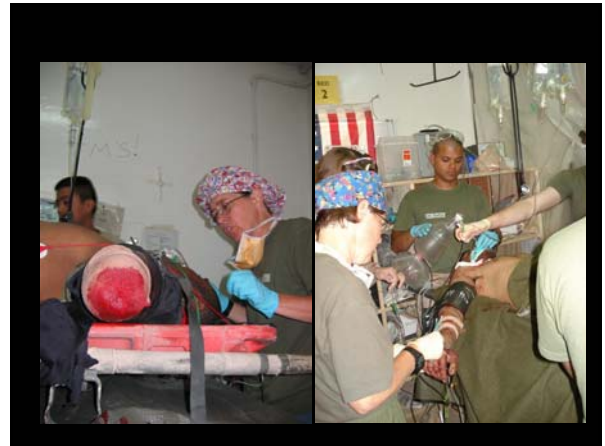- Down Range
  - Iraq - OIF
  - Afghanistan - OEF
- FOB
  - Forward Operating Base
  - FAST Team – Forward Surgical Team
- Evacuation Hospital
  - CASH

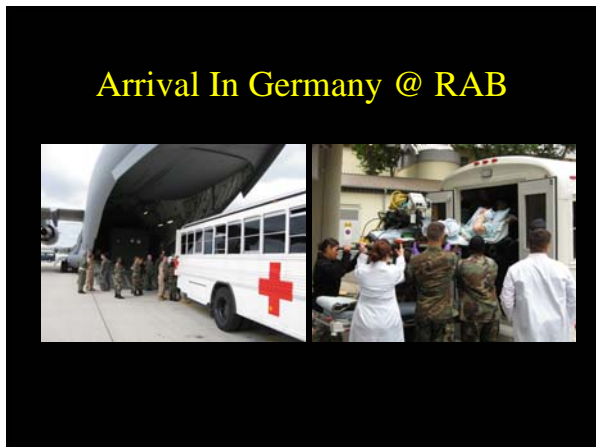
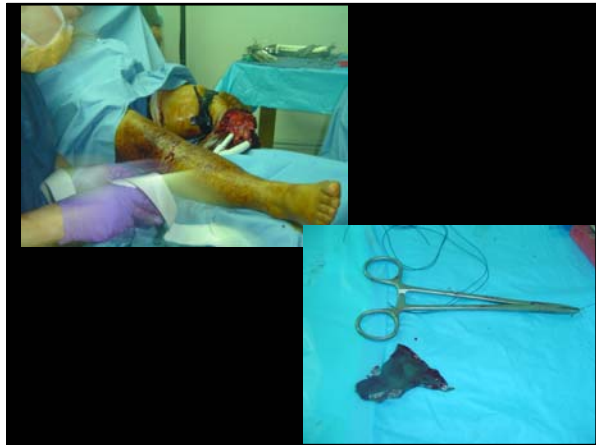
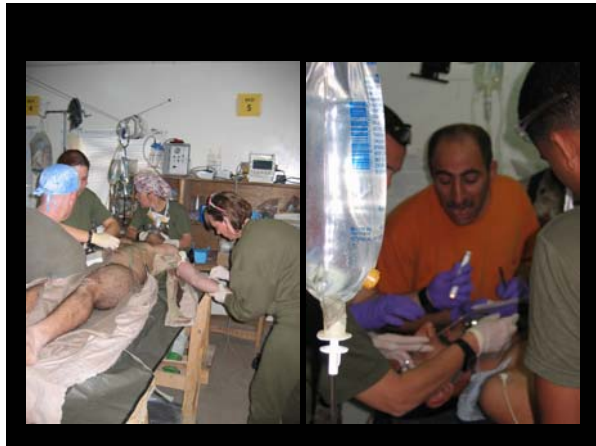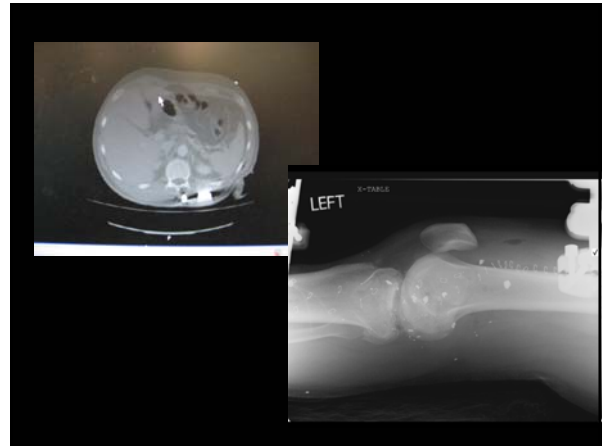
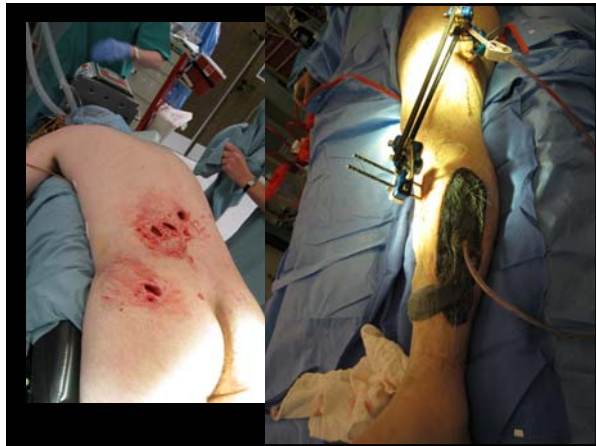**IED**  
Improvised Explosive Device



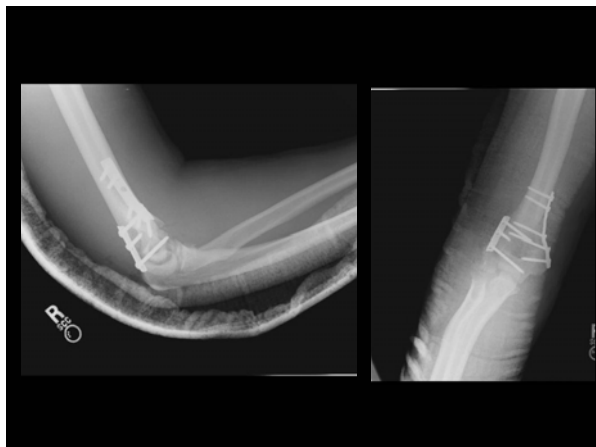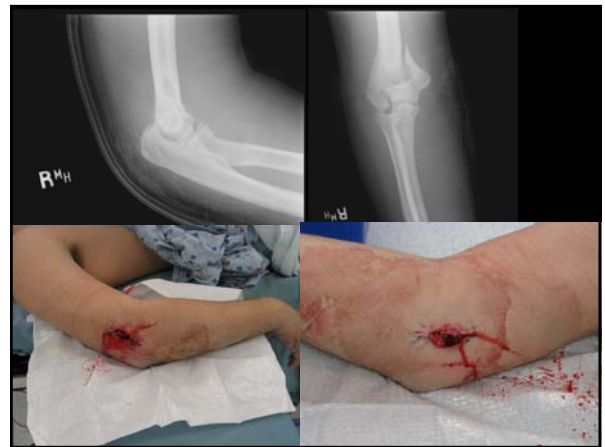**EPD**  
Explosive Penetrating Device

A composite image with a black background. On the left, the text "IED" is written in yellow, with "Improvised Explosive Device" below it. To the right is a photograph of a truck engulfed in flames. Below the text "EPD" is the text "Explosive Penetrating Device" in yellow. To the right of this text is a photograph of a destroyed vehicle being lifted by a crane.

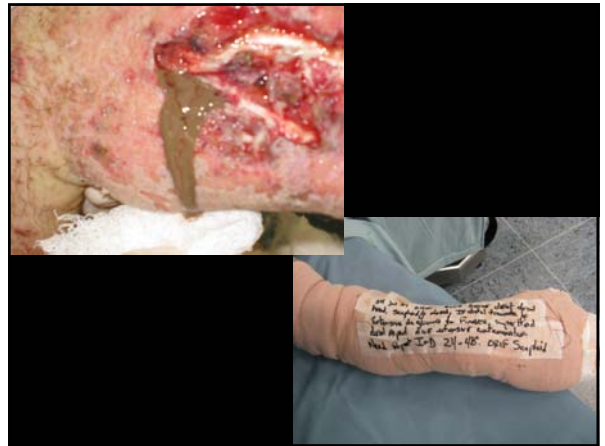
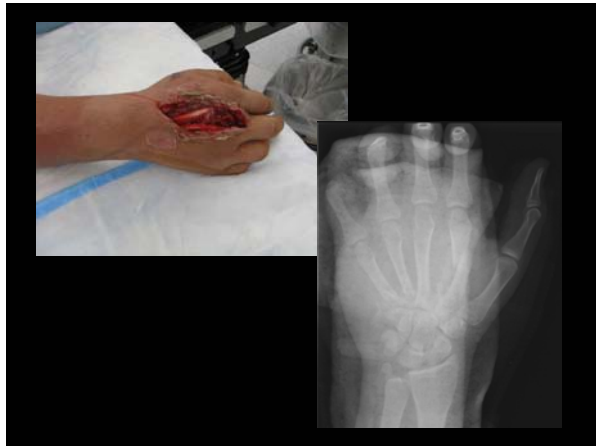


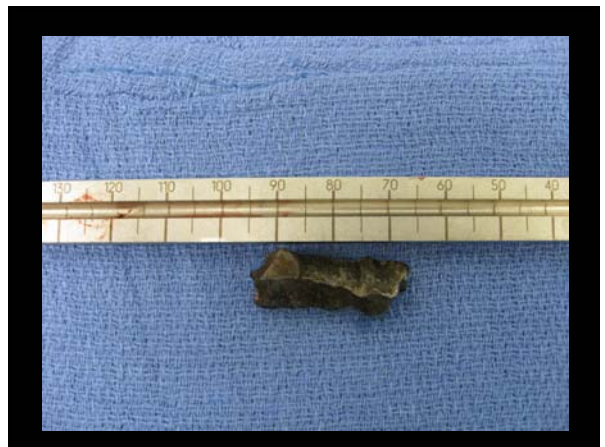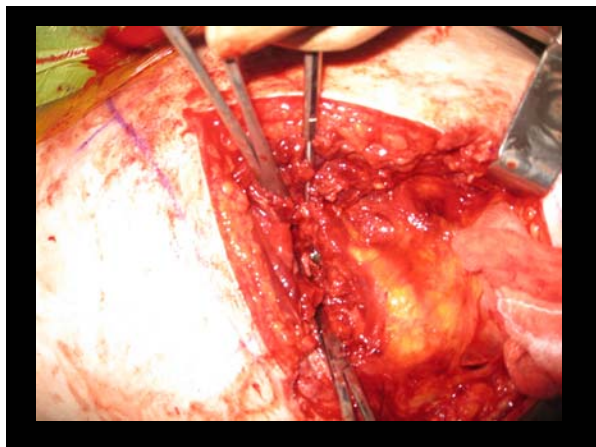
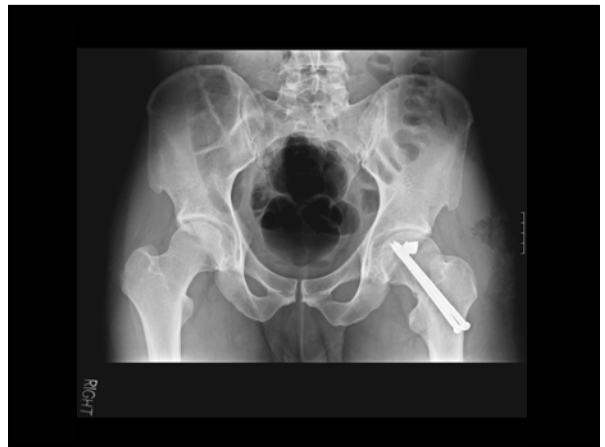Where Did The Two Dudes Go?



Soft Tissue Injuries and Contamination With a Twist?

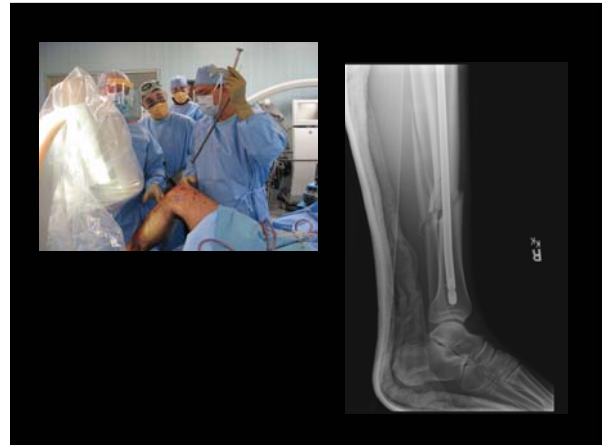
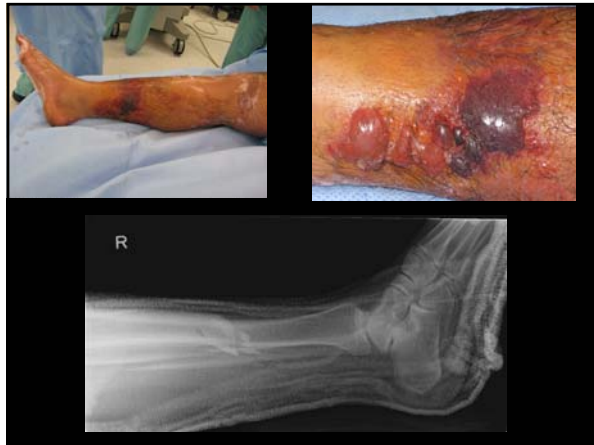
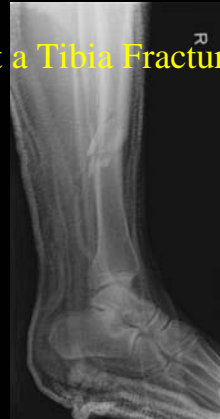Who Did This Operation Anyway ?

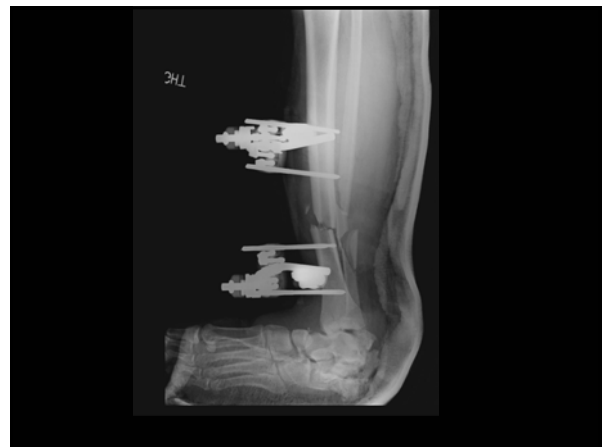

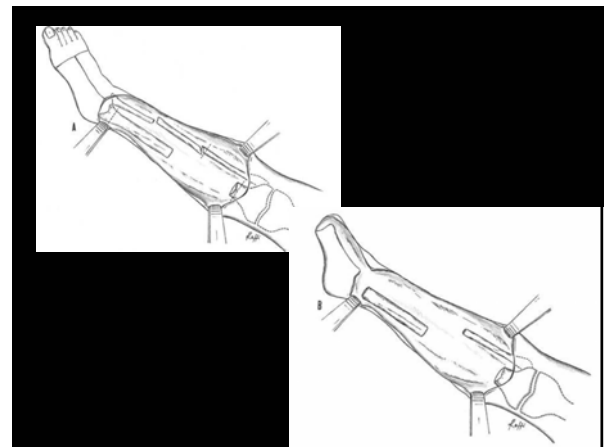
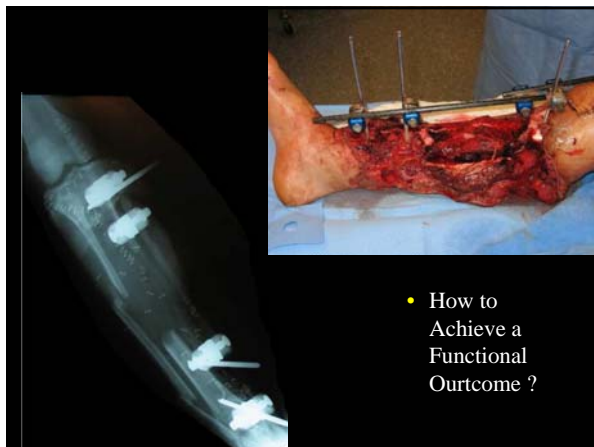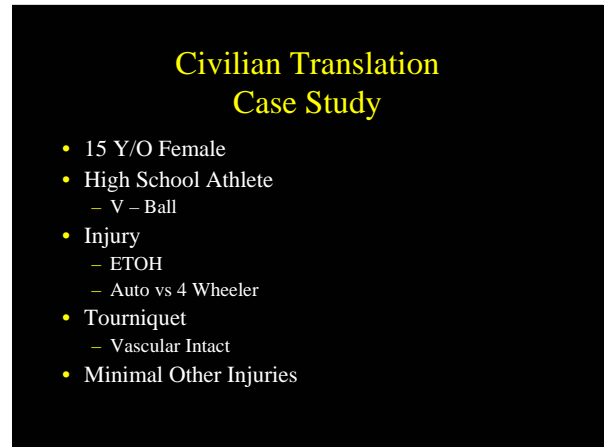
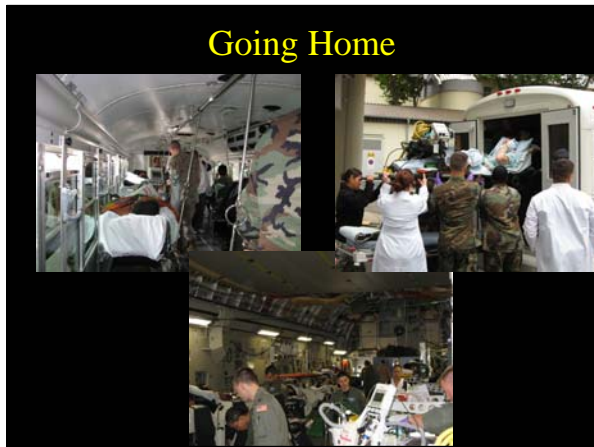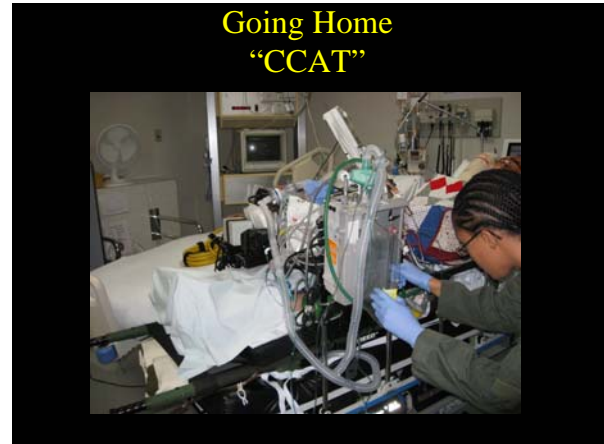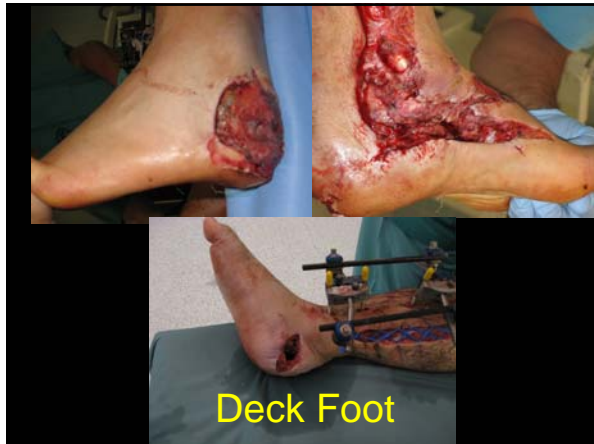Its Not Just Another Fracture?

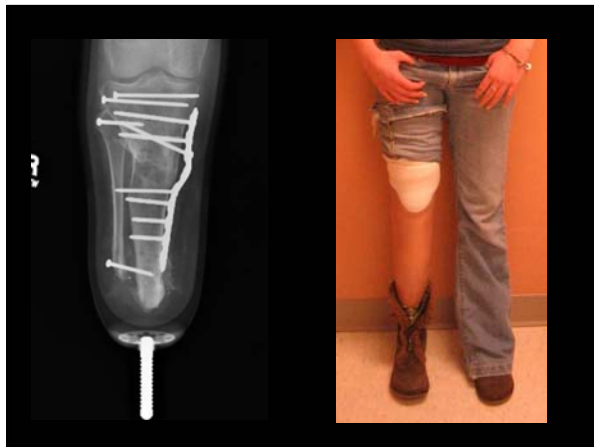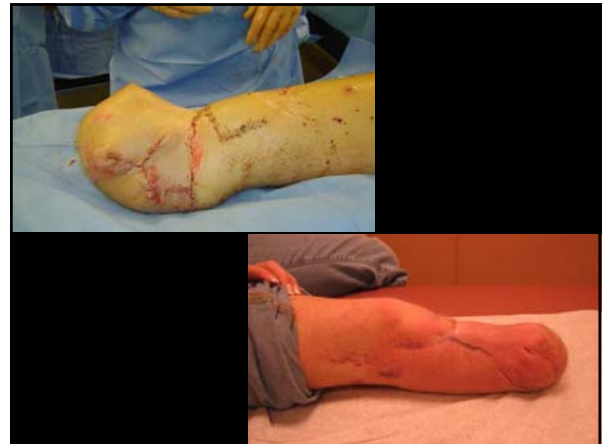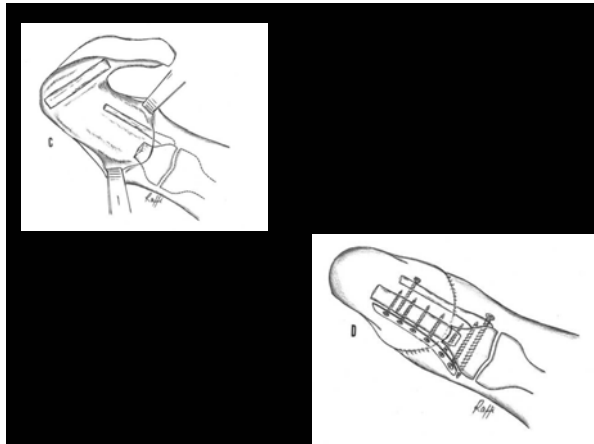
Its Just a Tibia Fracture Right?



Re-Emergence of an Old Condition  
“Institutional Memory”







### What I got out of it ?

- Humble
- Gained Experience in Caring for Acute Soft Tissue Trauma

### What They Got Out Of It ?

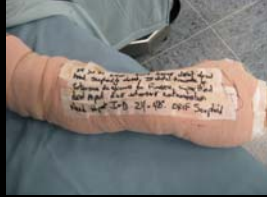- Weekly CME Lectures
- Clinical Training/Interaction With Civilian Experts
- Civilian Support To Correct Deficiencies with Command

### Collaboration Efforts

- War Extremity Injury Symposium
- Research Funding
- Strengthen Joint Efforts
  - Research and Training

## Medical Reminders

- Communication
- Social Work System
- Leadership



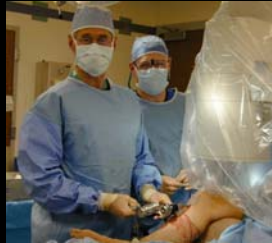## Medical Reminders

- Communication
- Social Work System
- Leadership



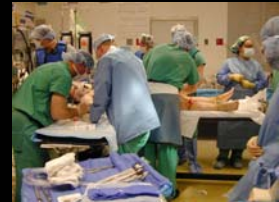## Medical Reminders

- Communication
- Social Work System
- Leadership



## Medical Advances

- Tourniquet
- Temporary Arterial Shunts
- Activated Factor VII
- Damage Control Surgery
- Soft Tissue and Bone Defect Resolution
  - BMP
- Amputation Care Advances



## What Can We Do ?

- Provide Homeland Leadership
  - Politically Active
  - Support The Reserves and National Guard
  - Disaster Preparedness

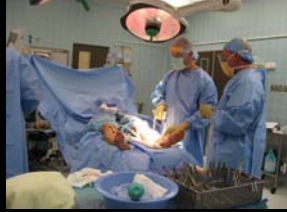## Recognition

- Major Funari RN
- Major Ortiz PAC
- Neil Cooper MD
- Charlie Pasque MD
- Dave Dromsky MD
- Troy Tolmack Sgt



## Recognition

- Major Funari RN
- Major Ortiz PAC
- Neil Cooper MD
- Charlie Pasque MD
- Dave Dromsky MD
- Troy Tolmack Sgt



## Recognition

- Major Funari RN
- Major Ortiz PAC
- Neil Cooper MD
- Charlie Pasque MD
- Dave Dromsky MD
- Troy Tolmack Sgt



## Program Future

- Downrange Visiting Surgeon Program ?
  - Controversial



## *Questions & Discussion*